

Longstanding Groin Pain

CHAPTER

24

WITH CHRIS BRADSHAW AND PER HOLMICH

Acute injuries to the hip and groin region have been discussed in Chapter 23. In this chapter we discuss the common presentation of exercise-related groin pain, frequently of a longstanding nature.

The anatomy of the groin area is shown in Figures 23.1 and 24.1.

Epidemiology, terminology and pathogenesis

Longstanding groin pain in athletes has been recognized in activities that combine high running loads, rapid changes of direction, and kicking.¹ The two most common sports associated with this syndrome are soccer and Australian football, which both require players to run fast and kick across the body. Longstanding groin pain is also a major concern in basketball, American football, Rugby and field hockey.

'Osteitis pubis' and other popular diagnoses

Non-specific exercise-related groin pain has been given many different 'diagnostic' labels; by far the most popular have been osteitis pubis (UK, Europe and Australia) and athletic pubalgia (North America). The term osteitis pubis was originally used to describe an infectious or inflammatory complication of suprapubic surgery.² It was subsequently used to describe the syndrome of exercise-related groin pain associated with radiographic bony changes at the symphysis pubis and/or increased uptake on radionuclide bone scan in the pubic symphysis. More recently, 'osteitis pubis' has become an umbrella term for all exercise-related groin pain in athletes. However, as longstanding groin pain is rarely inflammatory in nature, and the finding of increased uptake on bone

scan is not universal, the term osteitis pubis seems inappropriate. Thus, we, and an increasing number of clinicians who work with sportspeople, are avoiding the term 'osteitis pubis' when diagnosing longstanding groin pain. The term is both inaccurate with regard to pathology and confusing as it means different things to different people.

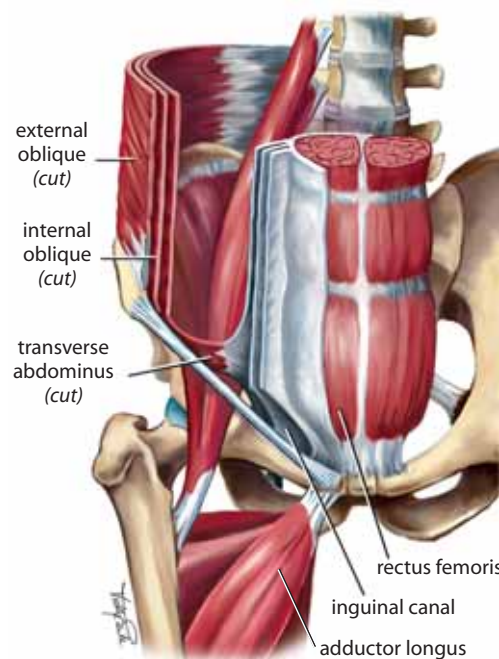
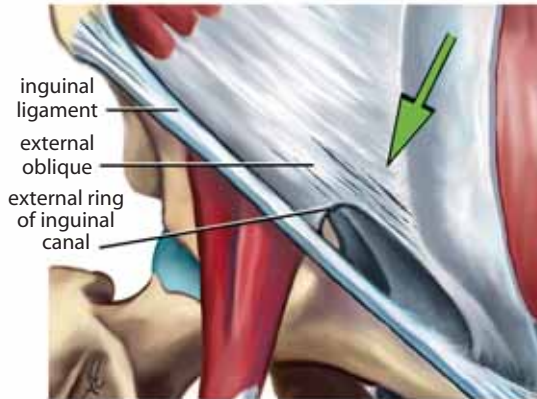
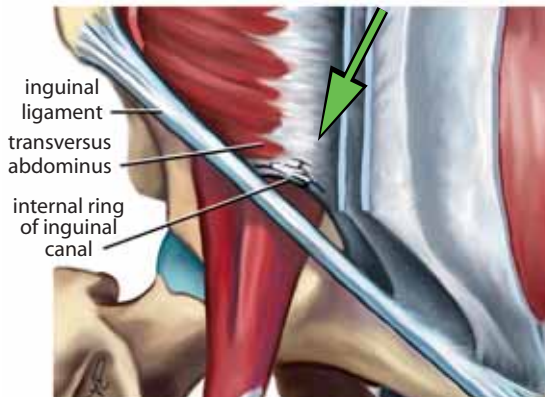


Figure 24.1 Anatomy of the groin area

(a) Muscles of the abdominal wall



(b) External oblique muscle showing common site of tears



(c) Transversus abdominis muscle showing common site of tears

Other ‘diagnoses’ of longstanding exercise-related groin pain include adductor tendinopathy/enthesopathy, iliopsoas dysfunction, posterior inguinal wall deficiency, sportsperson’s hernia, sports hernia, tear of external oblique aponeurosis, Gilmore’s groin and chronic adductor muscle strain. However, even though some clinicians believe that all longstanding groin pain in athletes has a single specific diagnosis, this is unlikely.

Local overload causing failure of various structures

Our clinical experience suggests that longstanding groin pain can be the end result of a number of different pathologies. By the time pain has been experienced for months, several pathologies may be present. The fundamental etiology is that mechanical *overload* of the pelvic region (i.e. due to sport) causes

failure of local tissue—muscle, tendon or bone alone or in combination.

PRACISE PEARL Expanding on Holmich et al.’s concept of three ‘diagnostic entities’,³ we assess the patient for evidence of one or more of four clinical entities (Table 24.1).

In our experience, usually more than one entity is present by the time the problem is recognized (Fig. 24.2). This is because they may have a common cause, or because the condition may commence as a single entity which then progresses to involve other areas. An example of how this develops is shown in the box.

Table 24.1 Four clinical entities that may be involved in longstanding groin pain

Clinical entity	Pathological elements likely to underpin the entity
Adductor related ³	Musculotendinous injuries, enthesopathy, neuromyofascial
Iliopsoas related ³	Neuromyofascial tightness, iliopsoas tendinopathy, lumbar spine abnormalities, iliopsoas bursitis (uncommon)
Abdominal wall related ⁴	Posterior inguinal wall weakness, conjoint tendon tear, external oblique aponeurosis tear
Pubic bone stress related ⁵	Stress reaction or stress fracture of the pubic bone

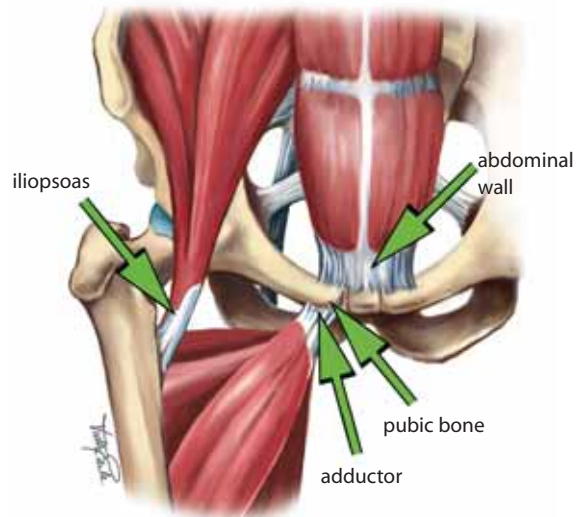


Figure 24.2 Overlapping clinical entities in longstanding groin pain in athletes